

A rare cause of inguinal mass

Saadia Ouarrak, Zineb Bouchbika, Nadia Benchakroun, Nezha Tawfiq, Hassan Jouhadi, Souha Sahraoui, Abdellatif Benider

CASE REPORT

A 42-year-old-man presented with one year history of abdominal pain and inguinal masses. The physical examination was notable for bilateral inguinal masses, the right one was an ulcero-vegetative tumor (Figure 1A) measuring 150 mm at its largest dimension, and vacuity of the right scrotum. Computed tomography of the abdomen, pelvis, and thorax showed a large mass involving under the right kidney, measuring 270 × 180 mm extended to the right inguinal region with bilateral inguinal adenopathy. The biopsy of the right inguinal mass was performed. The histologic analysis showed a testicular seminoma. Alpha fetoprotein and human chorionic gonadotrophin levels were negative. Lactate dehydrogenase level of 1759 units per liter (reference range, 140–280 units per liter). The patient received chemotherapy (cisplatin, etoposide, bleomycin) with good clinical response (Figure 1B). Computed tomography showed more than 90% regression of the mass. Lactate dehydrogenase level after chemotherapy was normal. The patient was lost to follow-up.

DISCUSSION

Cryptorchidism is the absence of one or both testes from the scrotum [1]. It is the most common birth defect of the male genitalia [2]. Lip et al. used meta-analysis to identify 12 series, they conclude that the relative risk

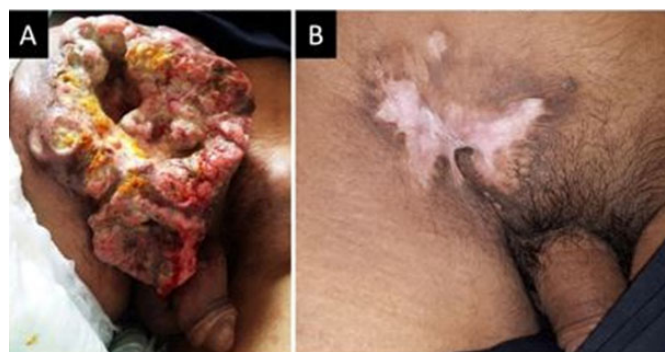

Figure 1: (A) Large inguinal mass, (B) Regression of the mass.

of having cryptorchidism and subsequent testicular malignancy is 2.9 [3].

Surgical treatment is mandatory, with resection of intra-abdominal mass and chemotherapy may be an alternative, depending on the stage [4].

CONCLUSION

Early diagnosis and treatment of cryptorchidism is very important to avoid the risk of developing germ cell tumors. Our case had a good response after chemotherapy.

Keywords: Chemotherapy, Cryptorchidism, Testicular seminoma

How to cite this article

Ouarrak S, Bouchbika Z, Benchakroun N, Tawfiq N, Jouhadi H, Sahraoui S, Benider A. A rare cause of inguinal mass. J Case Rep Images Urol 2021;6:100017Z15SO2021.

Article ID: 100017Z15SO2021

DOI: 10.5348/100015Z15SO2021CI

Saadia Ouarrak¹, MD, Zineb Bouchbika¹, MD, Nadia Benchakroun¹, MD, Nezha Tawfiq¹, MD, Hassan Jouhadi¹, MD, Souha Sahraoui¹, MD, Abdellatif Benider¹, MD

Affiliation: ¹Department of Radiation Oncology, University Hospital of Ibn Rochd, Casablanca, Morocco.

Corresponding Author: Saadia Ouarrak, Department of Radiation Oncology, University Hospital of Ibn Rochd, 1 rue des hôpitaux, Casablanca 20250, Morocco; Email: saadia10406@gmail.com

Received: 23 May 2021

Accepted: 11 July 2021

Published: 12 August 2021

REFERENCES

1. Kilgour FG. Stedman’s medical dictionary. Yale J Biol Med 1953;26(2):175.
2. Wood HM, Elder JS. Cryptorchidism and testicular cancer: Separating fact from fiction. J Urol 2009;181(2):452–61.
3. Lip SZL, Murchison LED, Cullis PS, Govan L, Carachi R. A meta-analysis of the risk of boys with isolated cryptorchidism developing testicular cancer in later life. Arch Dis Child 2013;98(1):20–6.
4. Lim YJ, Jeong MJ, Bae BN, Kim SH, Kim JY. Seminoma in undescended testis. Abdom Imaging 2008;33(2):241–3.

Author Contributions

Saadia Ouarrak – Conception of the work, Design of the work, Acquisition of data, Analysis of data, Interpretation of data, Drafting the work, Revising the work critically for important intellectual content, Final approval of the version to be published, Agree to be accountable for all aspects of the work in ensuring that questions related to the accuracy or integrity of any part of the work are appropriately investigated and resolved

Zineb Bouchbika – Interpretation of data, Drafting the work, Final approval of the version to be published, Agree to be accountable for all aspects of the work in ensuring that questions related to the accuracy or integrity of any part of the work are appropriately investigated and resolved

Nadia Benchakroun – Interpretation of data, Drafting the work, Final approval of the version to be published, Agree to be accountable for all aspects of the work in ensuring that questions related to the accuracy or integrity of any part of the work are appropriately investigated and resolved

Nezha Tawfiq – Interpretation of data, Drafting the work, Final approval of the version to be published, Agree to be accountable for all aspects of the work in ensuring that questions related to the accuracy or integrity of any part of the work are appropriately investigated and resolved

Hassan Jouhadi – Interpretation of data, Drafting the work, Final approval of the version to be published, Agree

to be accountable for all aspects of the work in ensuring that questions related to the accuracy or integrity of any part of the work are appropriately investigated and resolved

Souha Sahraoui – Interpretation of data, Drafting the work, Final approval of the version to be published, Agree to be accountable for all aspects of the work in ensuring that questions related to the accuracy or integrity of any part of the work are appropriately investigated and resolved

Abdellatif Benider – Interpretation of data, Revising the work critically for important intellectual content, Final approval of the version to be published, Agree to be accountable for all aspects of the work in ensuring that questions related to the accuracy or integrity of any part of the work are appropriately investigated and resolved

Guarantor of Submission

The corresponding author is the guarantor of submission.

Source of Support

None.

Consent Statement

Written informed consent was obtained from the patient for publication of this article.

Conflict of Interest

Authors declare no conflict of interest.

Data Availability

All relevant data are within the paper and its Supporting Information files.

Copyright


© 2021 Saadia Ouarrak et al. This article is distributed under the terms of Creative Commons Attribution License which permits unrestricted use, distribution and reproduction in any medium provided the original author(s) and original publisher are properly credited. Please see the copyright policy on the journal website for more information.

Access full text article on other devices



Access PDF of article on other devices





INTERNATIONAL JOURNAL OF
CASE REPORTS AND IMAGES



VIDEO JOURNAL OF
CLINICAL RESEARCH



VIDEO JOURNAL OF
BIOMEDICAL SCIENCE



INTERNATIONAL JOURNAL OF
HEPATOBIILIARY AND
PANCREATIC DISEASES



INTERNATIONAL JOURNAL OF
BLOOD TRANSFUSION AND
IMMUNOHEMATOLOGY

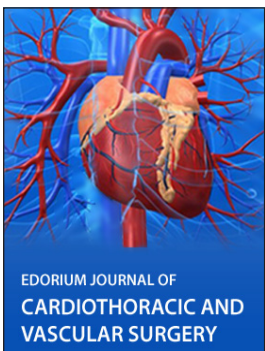

EDORIUM JOURNAL OF
OPHTHALMOLOGY

Submit your manuscripts at
www.edoriumjournals.com



EDORIUM JOURNAL OF
MEDICINE



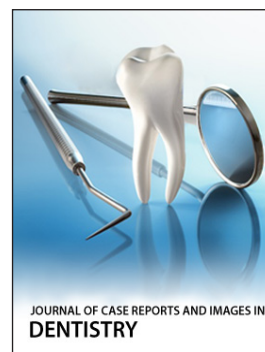EDORIUM JOURNAL OF
CARDIOTHORACIC AND
VASCULAR SURGERY



EDORIUM JOURNAL OF
PSYCHOLOGY



EDORIUM JOURNAL OF
CELL BIOLOGY



JOURNAL OF CASE REPORTS AND IMAGES IN
DENTISTRY



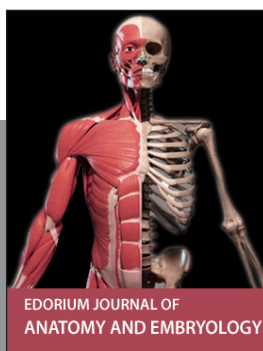EDORIUM JOURNAL OF
CANCER



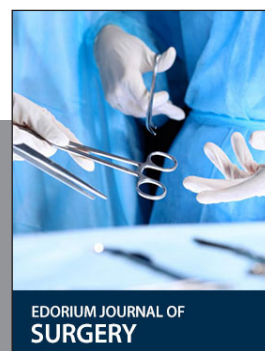
EDORIUM JOURNAL OF
PSYCHIATRY



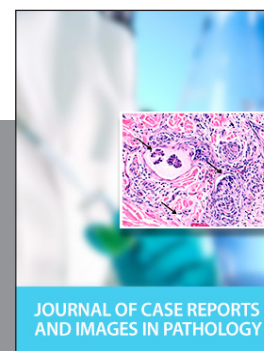JOURNAL OF CASE REPORTS AND
IMAGES IN INFECTIOUS DISEASES



EDORIUM JOURNAL OF
ANATOMY AND EMBRYOLOGY



EDORIUM JOURNAL OF
SURGERY



JOURNAL OF CASE REPORTS
AND IMAGES IN PATHOLOGY



EDORIUM JOURNAL OF
ANESTHESIA